

Arteries of the Upper Extremity

- 1 Thyrocervical trunk
- 2 Suprascapular a.
- 3 Transverse cervical a.

- 4 Thoracoacromial trunk (Tat)
- 5 Pectoral branch of Tat
- 6 Deltoid branch of Tat
- 7 Acromial branch of Tat
- 8 Clavicular branch of Tat
- 9 Internal thoracic a.
- 10 Supreme thoracic a.
- 11 Lateral thoracic a.
- 12 Axillary a.
- 13 Subscapular a.
- 14 Circumflex scapular a.
- 15 Thoracodorsal a.
- 16 Posterior humeral circumflex a.
- 17 Anterior humeral circumflex a.
- 18 Brachial a.
- 19 Deep brachial a.
- 20 Superior ulnar collateral a.
- 21 Inferior ulnar collateral a.
- 22 Middle collateral a.
- 23 Radial collateral a.
- 24 Posterior ulnar recurrent a.
- 25 Anterior ulnar recurrent a.
- 26 Interosseus recurrent a.
- 27 Radial recurrent a.

- 28 Ulnar a.

- 29 Radial a.

- 30 Common interosseus a.
- 31 Anterior interosseus a.

- 32 Posterior interosseus a.

- 33 Deep palmar branch of ulnar a.

- 34 Superficial palmar branch of radial a.

- 35 Deep palmar arch

- 36 Superficial palmar arch
- 37 Common digital aa.
- 38 Proper digital aa.

Vascularization of Upper Extremity

- 1
- 2 Supraspinatus, Infraspinatus
- 3 Trapezius, Latissimus dorsi, Levator scapulae, Rhomboideus major

- 4
- 5 Pectoralis major & minor
- 6 Deltoideus
- 7
- 8 Subclavius
- 9
- 10
- 11 Serratus anterior, Subscapularis
- 12
- 13 Latissimus dorsi, Subscapularis
- 14 Infraspinatus, Teres minor & major
- 15 Latissimus dorsi
- 16 Deltoideus
- 17
- 18 Coracobrachialis, Biceps brachii, Brachialis
- 19 Triceps brachii
- 20
- 21
- 22
- 23
- 24 Palmaris longus, Flexor carpi ulnaris
- 25 Pronator teres
- 26 Anconeus
- 27 Brachialis, Brachioradialis, Extensor carpi radialis longus & brevis, Supinator
- 28 Flexor digitorum superficialis, Flexor digitorum profundus
- 29 Flexor carpi radialis, Flexor digitorum superficialis, Extensor carpi radialis longus & brevis
- 30
- 31 Flexor digitorum profundus, Flexor pollicis longus, Pronator quadratus
- 32 Flexor digitorum, Extensor digiti minimi, Extensore carpi ulnaris, Supinator, Abductor pollicis longus, Extensor pollicis brevis, Extensor pollicis longus, Extensor indicis
- 33 Abductor digiti minimi, Flexor digiti minimi brevis, Opponens digiti minimi
- 34 Abductor pollicis brevis, Opponens pollicis, Flexor pollicis brevis
- 35 Adductor pollicis, Lumbricales, Palmar & dorsal interossei
- 36 Palmaris bevis
- 37
- 38

Nerves of Upper Extremity

- 1 Long thoracic n.
- 2 Dorsal scapular n.

- 3 N. to subclavius
- 4 Suprascapular n.
- 5 Lateral anterior thoracic n. (lateral pectoral n.)
- 6 Upper subscapular n.
- 7 Thoracodorsal n.
- 8 Lower subscapular n.
- 9 Medial anterior thoracic n. (medial pectoral n.)
- 10 Medial brachial cutaneous n.
- 11 Medial antebrachial cutaneous n.
- 12 Musculocutaneous n. (to lateral antebrachial cutaneous n.)
- 13 Axillary n.
- 14 Upper trunk
- 15 Middle trunk
- 16 Lower trunk
- 17 Lateral cord
- 18 Posterior cord
- 19 Medial cord
- 20 Radial n.

- 21 Median n.

- 22 Ulnar n.

- 23 Posterior interosseus n. (of radial n.)

- 24 Superficial radial n.
- 25 Anterior interosseus n. (of radial n.)

- 26 Median n.
- 27 Dorsal branch of ulnar n.
- 28 Muscular branches of median n.

- 29 Superficial palmar n. (of ulnar n.)
- 30 Deep palmar n. (of ulnar n.)

- 31 Digital branches of median and ulnar nn.

Innervation of Upper Extremity

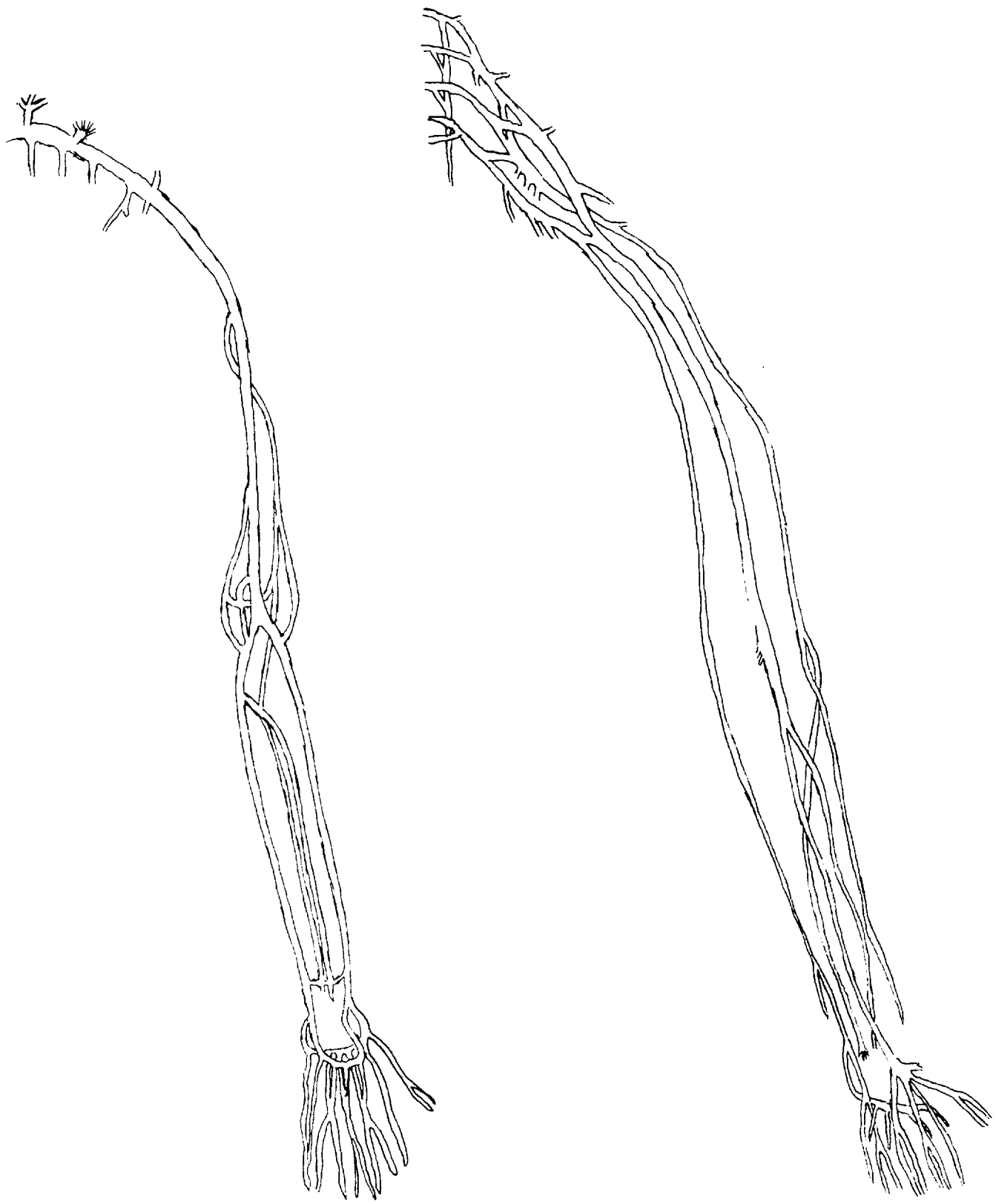
- 1 Serratus anterior
- 2 Levator scapulae, Rhomboideus major & minor
- 3 Subclavius
- 4 Supraspinatus & Infraspinatus
- 5 Pectoralis major

- 6 Subscapularis
- 7 Latissimus dorsi
- 8 Subscapularis, Teres major
- 9 Pectoralis major & minor

- 10
- 11
- 12 Coracobrachialis, Biceps brachii, Brachialis

- 13 Deltoideus, Teres minor
- 14
- 15
- 16
- 17
- 18
- 19
- 20 Triceps brachii, Brachioradialis, Extensor carpi radialis longus, Anconeus
- 21 Pronator teres, Flexor carpi radialis, Palmaris longus, Flexor digitorum superficialis
- 22 Flexor carpi ulnaris, Flexor digitorum profundus (medial half)
- 23 Extensor carpi radialis brevis, extensor digitorum, Extensor digiti minimi, Extensor carpi ulnaris, Supinator, Abductor pollicis longus, Extensor pollicis brevis, Extensor pollicis longus, Extensor indicis
- 24
- 25 Flexor digitorum profundus (lateral half), Flexor pollicis longus, Pronator quadratus
- 26 Lumbricales (1 st & 2nd)
- 27
- 28 Abductor pollicis brevis, Opponens pollicis, Flexor pollicis brevis
- 29 Palmaris brevis
- 30 Flexor pollicis brevis, Adductor pollicis, Abductor digiti minimi, Flexor digiti minimi brevis, Opponens digiti minimi, Lumbricales (3rd & 4th), Interossei (anterior & posterior)

- 31



Arteries of the Lower Extremity

- 1 Hypogastric trunk
- 2 Iliolumbar a.
- 3 Superior gluteal a.

- 4 Inferior gluteal a.

- 5 Obturator a.

- 6 External iliac a.
- 7 Femoral a.
- 8 Popliteal a.

- 9 Deep femoral a.
- 10 Medial circumflex femoral a.

- 11 Lateral circumflex femoral a.

- 12 Ascending branch of LCF
- 13 Descending branch of LCF
- 14 Perforating aa.

- 15 Descending genicular a.
- 16 Medial superior genicular a.
- 17 Lateral superior genicular a.
- 18 Medial inferior genicular a.
- 19 lateral inferior genicular a.
- 20 Anterior tibial recurrent a.
- 21 Anterior tibial a.

- 22 Posterior tibial a.
- 23 Peroneal a.

- 24 Anterior lateral malleolar a.
- 25 Lateral plantar a.

- 26 Medial plantar a.
- 27 Plantar arch
- 28 Dorsal metatarsal aa.
- 29 Plantar metatarsal aa.

- 30 Digital branches
- 31 Dorsalis pedis a.

Vascularization of Lower Extremity

- 1
- 2 Psoas major, Iliacus
- 3 Iliacus, Gluteus maximus, medius & minimus, Tensor fascia latae, Piriformis, Obturator internus
- 4 Gluteus maximus, Piriformis, Superior & inferior gemelli
- 5 Gracilis, Pectineus, Adductor longus, brevis & magnus, Obturator externus
- 6
- 7 Sartorius, Vastus medialis
- 8 Vastus medialis, Adductor magnus, Biceps femoris, Semitendinosus, Semimembranosus, Gastrocnemius, Soleus, Plantaris, Popliteus
- 9 Vastus medialis, Gracilis
- 10 Gracilis, Pectineus, Adductor longus, brevis & magnus, Quadratus femoris, Obturator externus
- 11 Rectus femoris, Vastus lateralis & intermedius, Tensor fascia latae
- 12
- 13
- 14 Adductor magnus, Gluteus maximus, Biceps femoris, Semitendinosus, Semimembranosus
- 15
- 16
- 17 Vastus lateralis
- 18
- 19
- 20
- 21 Tibialis anterior, Extensor hallucis longus, Extensor digitorum longus, Peroneus longus & tertius
- 22 Soleus, Flexor digitorum longus
- 23 Soleus, Flexor hallucis longus, Tibialis posterior, Peroneus longus & brevis
- 24
- 25 Abductor digiti minimi, Quadratus plantae, Flexor digiti minimi brevis
- 26 Adductor hallucis, Flexor digitorum brevis
- 27
- 28 Dorsal interossei
- 29 Lumbricales, Flexor hallucis brevis, Adductor hallucis, Plantar interossei
- 30
- 31 Extensor digitorum brevis

Nerves of Lower Extremity

- 1 Lateral femoral cutaneous n
- 2 N. to iliopsoas
- 3 N. to iliopsoas
- 4 Obturator n.

- 5 Superior gluteal n.

- 6 Inferior gluteal n.
- 7 N. to obturator internus
- 8 N. to quadratus femoris
- 9 Sciatic n.

- 10 Femoral n.
- 11 Muscular branches of femoral n.

- 12 Saphenous n.
- 13 Tibial n.

- 14 Common peroneal n.
- 15 Common sural n.
- 16 Superficial peroneal n.
- 17 Deep peroneal n. (Anterior tibial n.)

- 18 Intermediate dorsal cutaneous n.
- 19 Medial dorsal cutaneous n.
- 20 Lateral plantar n.

- 21 Medial plantar n.

- 22 Deep branch of lateral plantar n.

- 23 Digital branches

Innervation of Lower Extremity

- 1
- 2
- 3
- 4 Gracilis (ant), Adductor longus, brevis & magnus (ant), Obturator externus (post)
- 5 Gluteus medius & minimus, Tensor fasciae latae
- 6 Gluteus maximus
- 7 Obturator internus, Gemellus superior
- 8 Gemellus inferior, Quadratus femoris
- 9 Long (tibial) & short (peroneal) head of biceps femoris, Semitendinosus (tibial), Semimembranosus (tibial)
- 10
- 11 Iliacus, Sartorius, Rectus femoris, Vastus lateralis, medialis & intermedius, Pectineus
- 12
- 13 Gastrocnemius, Soleus, Plantaris, Flexor hallucis longus, Flexor digitorum longus, Tibialis posterior
- 14
- 15
- 16 Peroneus longus & brevis
- 17 Tibialis anterior, Extensor hallucis longus, Extensor digitorum longus, Peroneus tertius, Extensor digitorum brevis
- 18
- 19
- 20 Abductor digiti minimi, Quadratus plantae, Flexor digiti minimi brevis
- 21 Abductor hallucis, Flexor digitorum brevis, Lumbricales, Flexor hallucis brevis
- 22 Lumbricales, Adductor hallucis, Plantar & dorsal interossei
- 23

